

La **DIAGNOSTICA** **EMATOPATOLOGICA** nell'ERA della **MEDICINA** di **PRECISIONE**

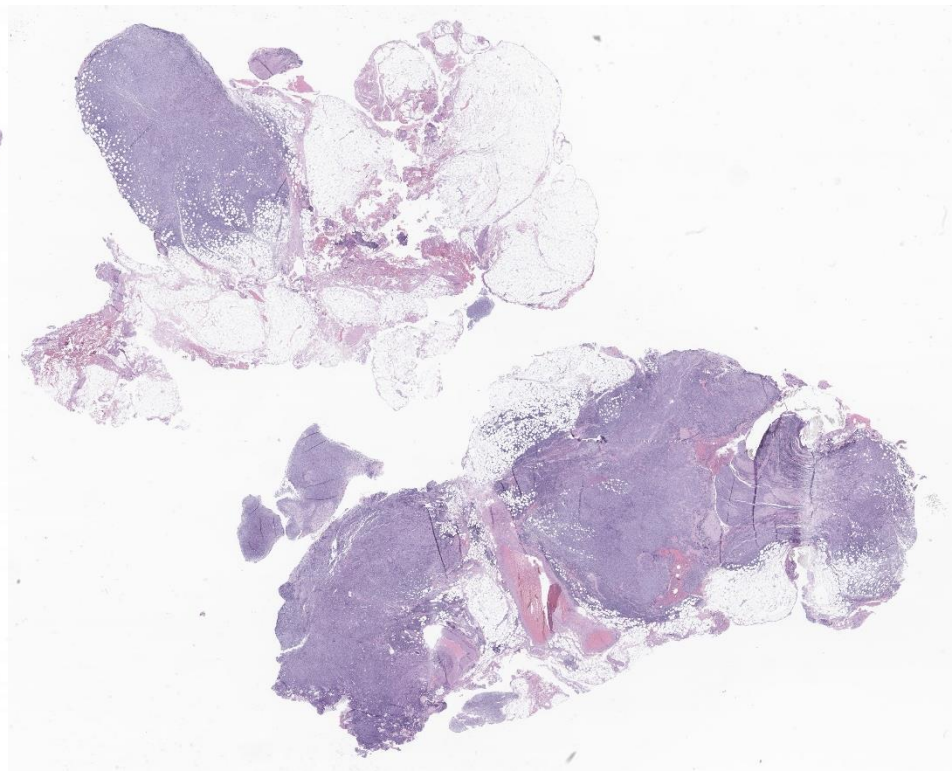
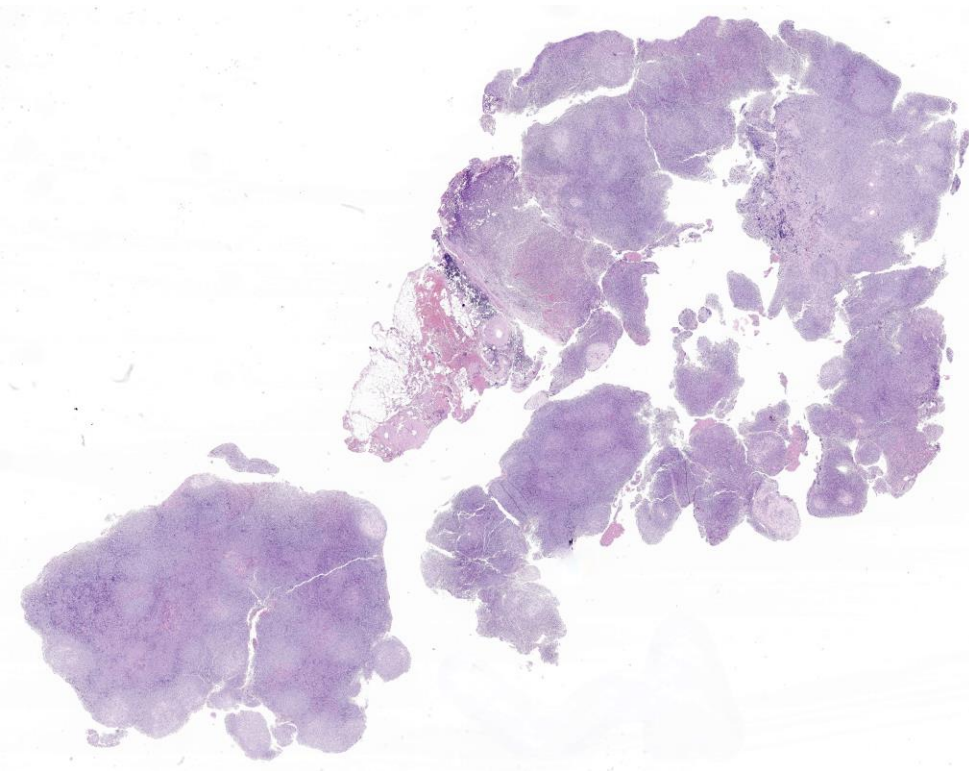
CLINICAL CASE

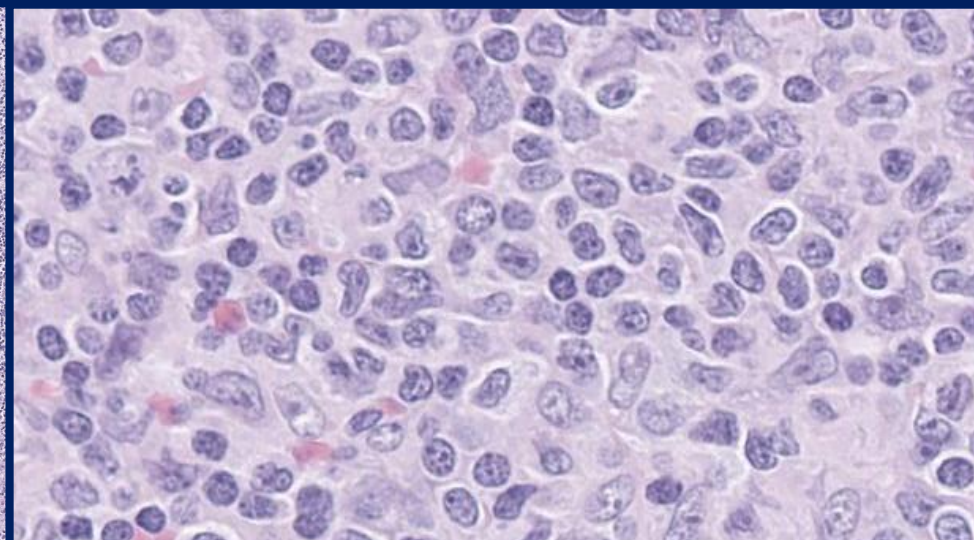
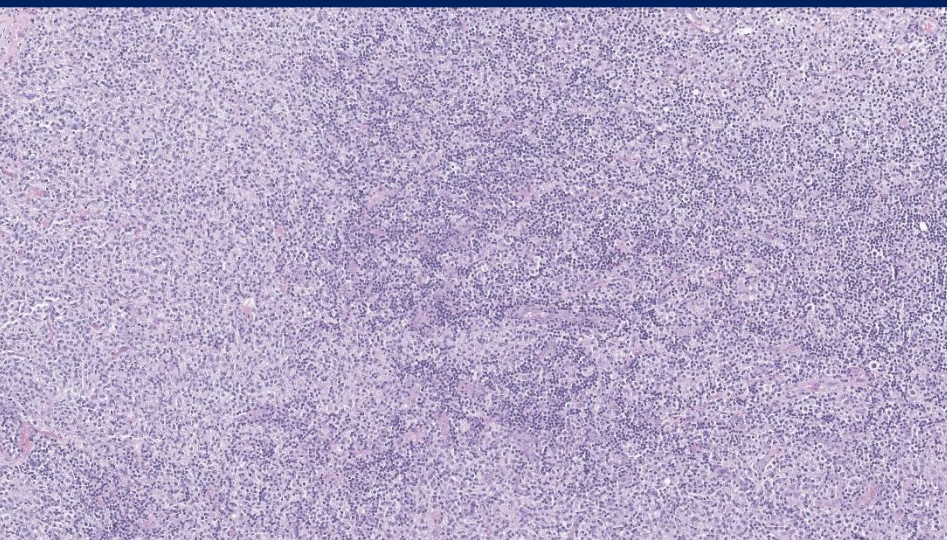
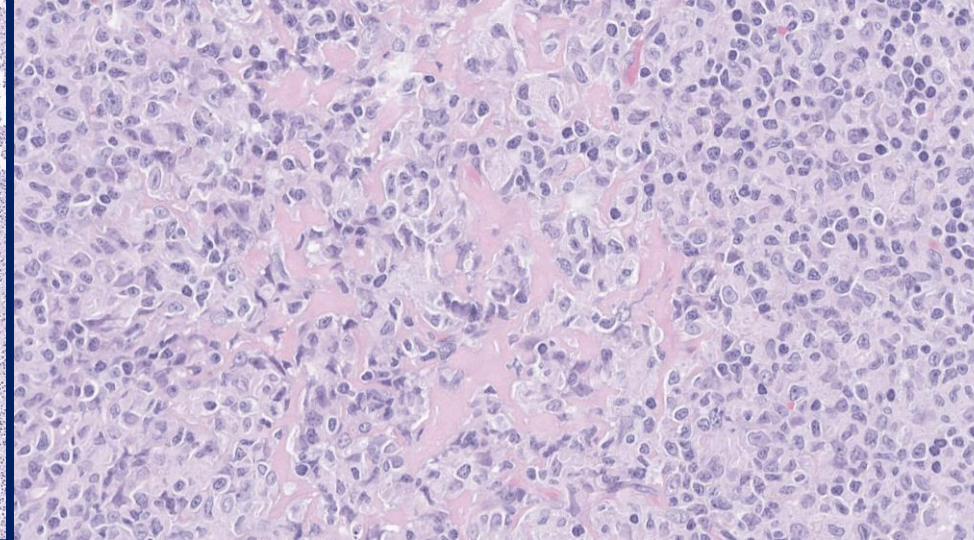
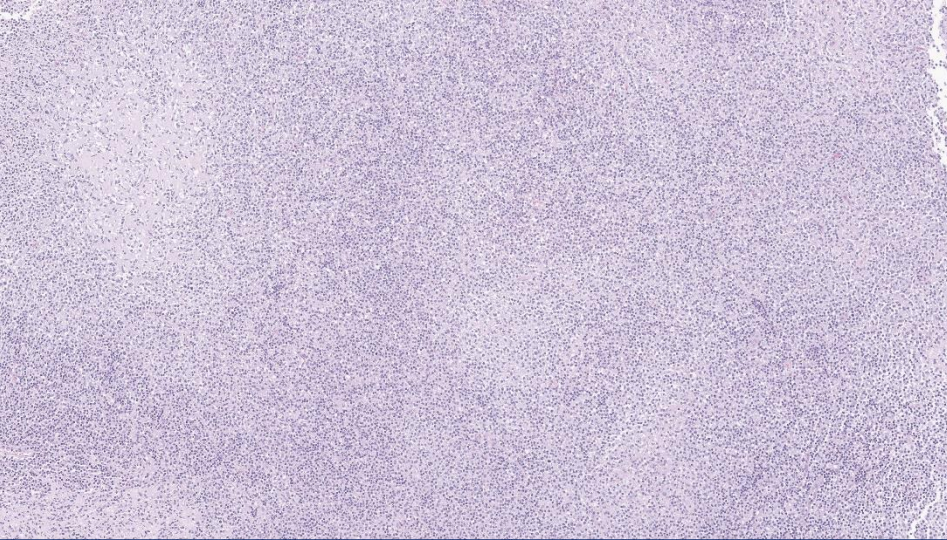
Paola Rizzo / Iacopo Ghini

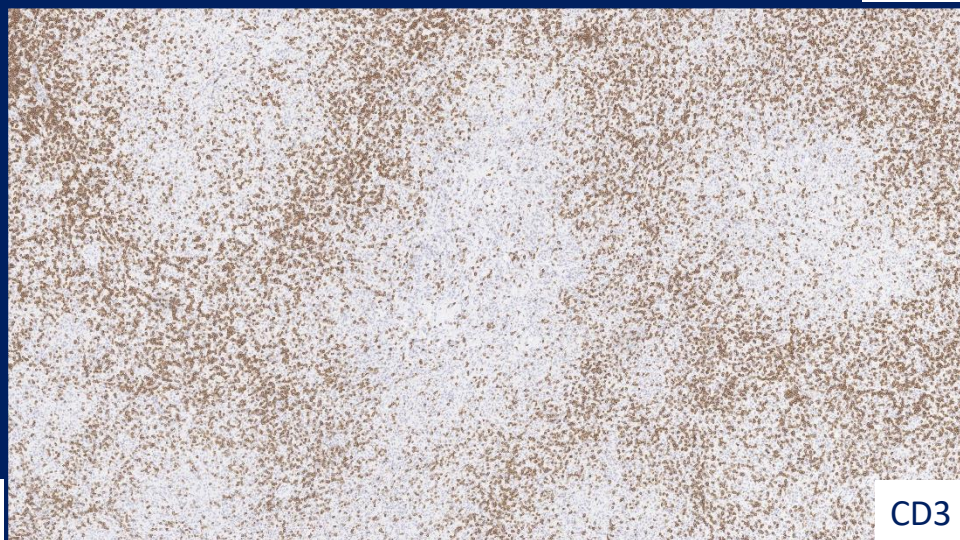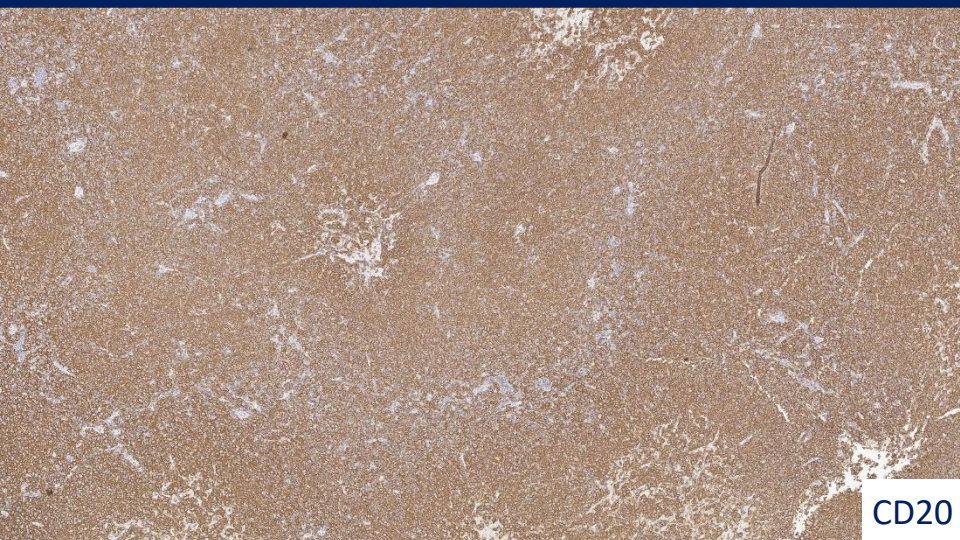
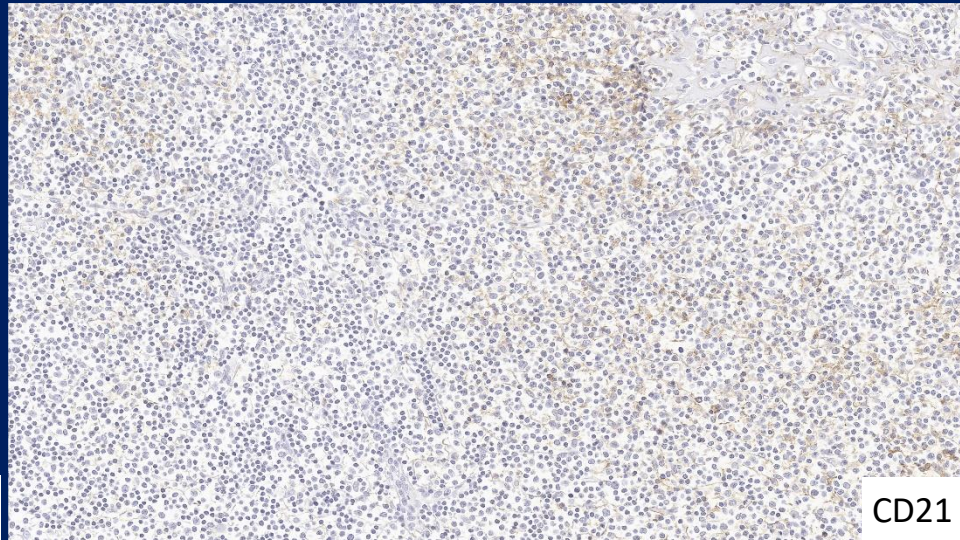
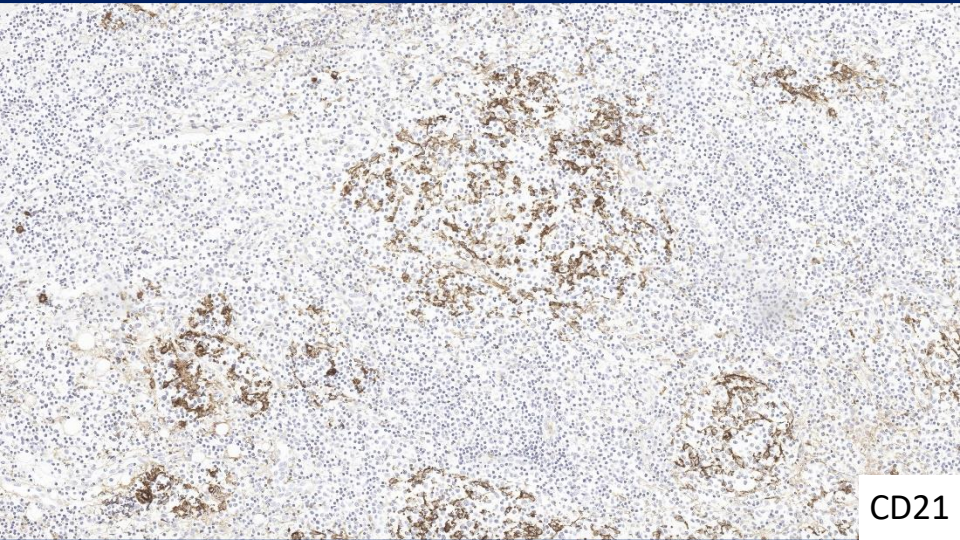
AOUI Verona/ASST Spedali Civili di Brescia

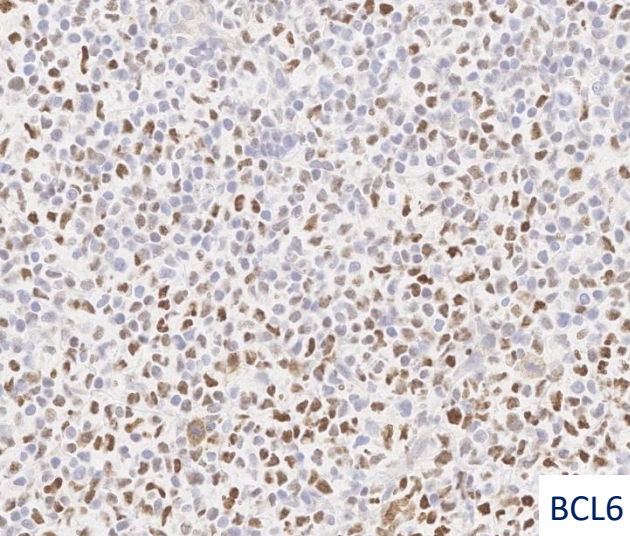


74 YRS October 2025: inguinal lymphadenopathy (lymph node conglomerate 4.5 cm)

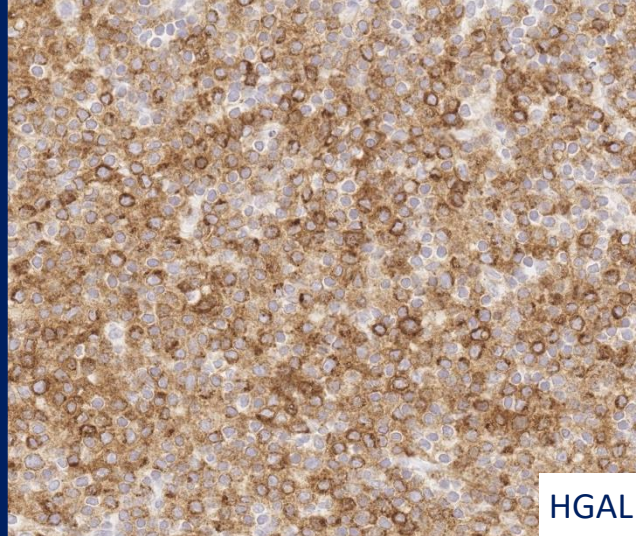




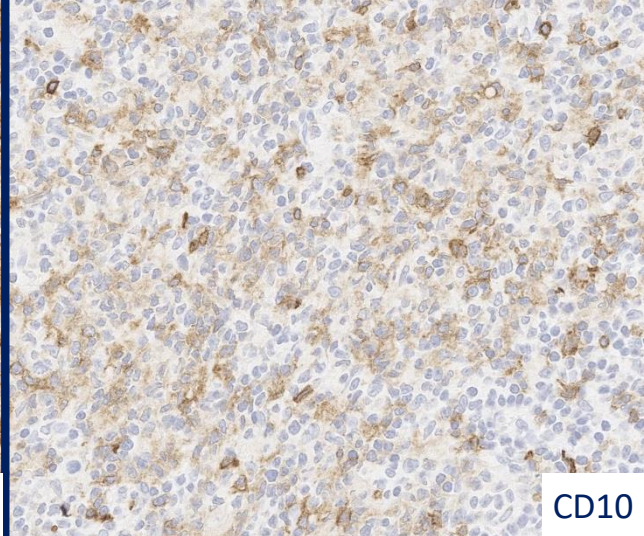




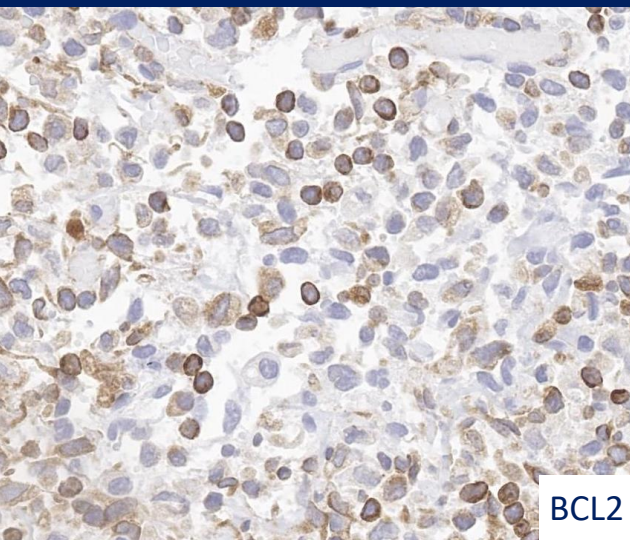
BCL6



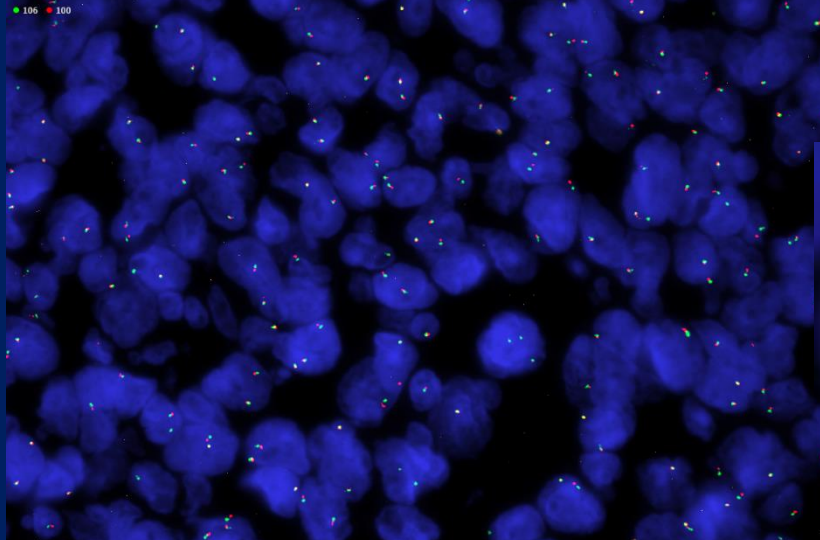
HGAL



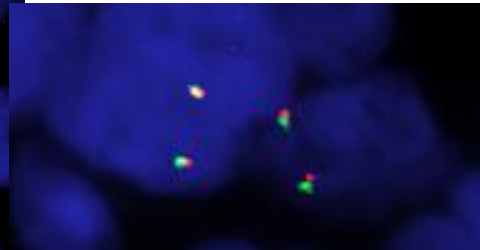
CD10

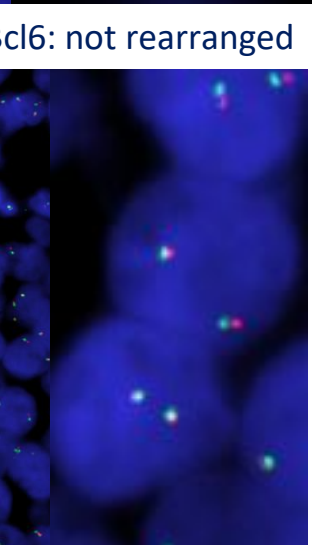
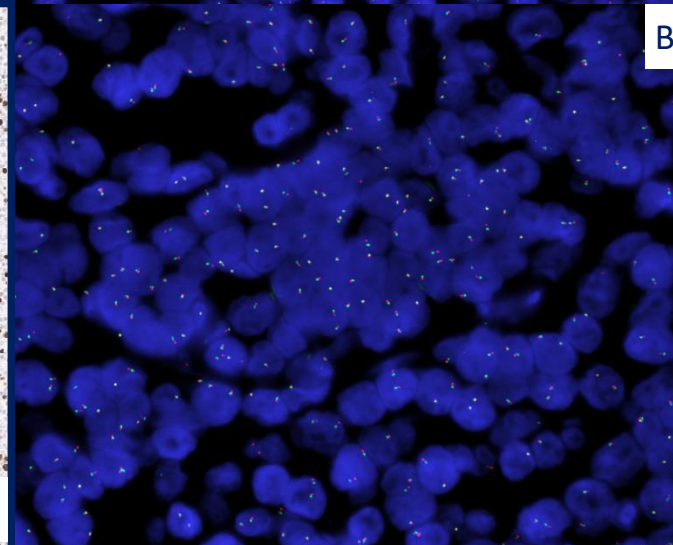
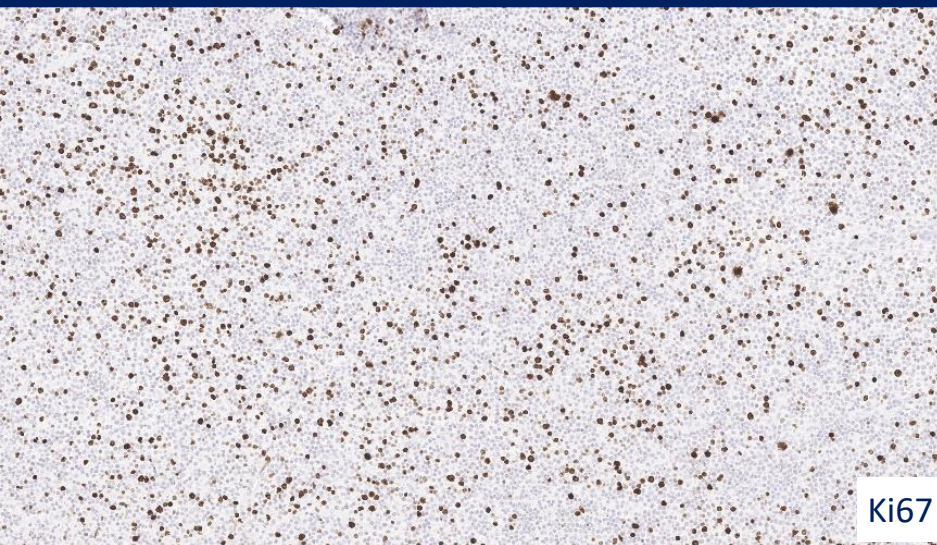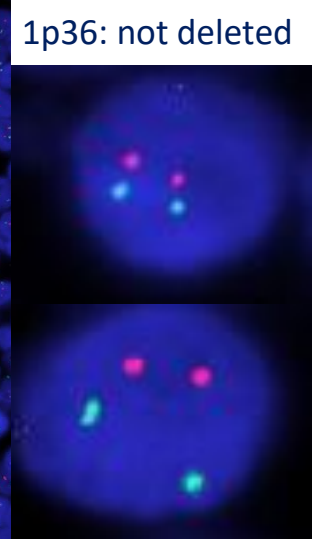
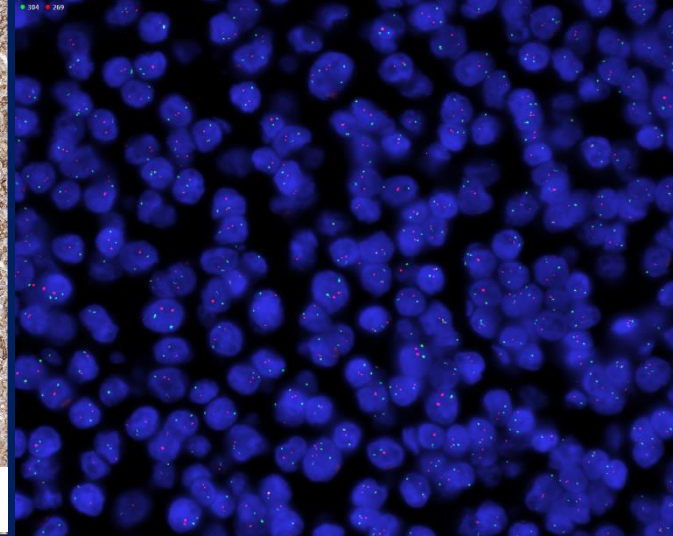
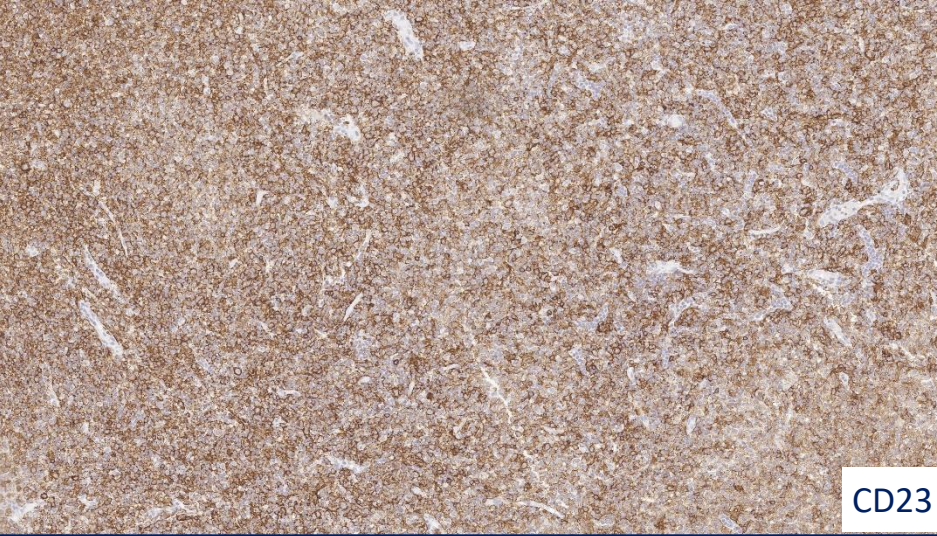


BCL2



Bcl2: not rearranged





DIAGNOSIS

BCL2-R–negative CD23-positive follicle centre lymphoma (ICC 2025)
Follicle centre lymphoma with dominant diffuse growth pattern (WHO 2024)

December 2025: bone marrow biopsy negative for neoplastic infiltration.

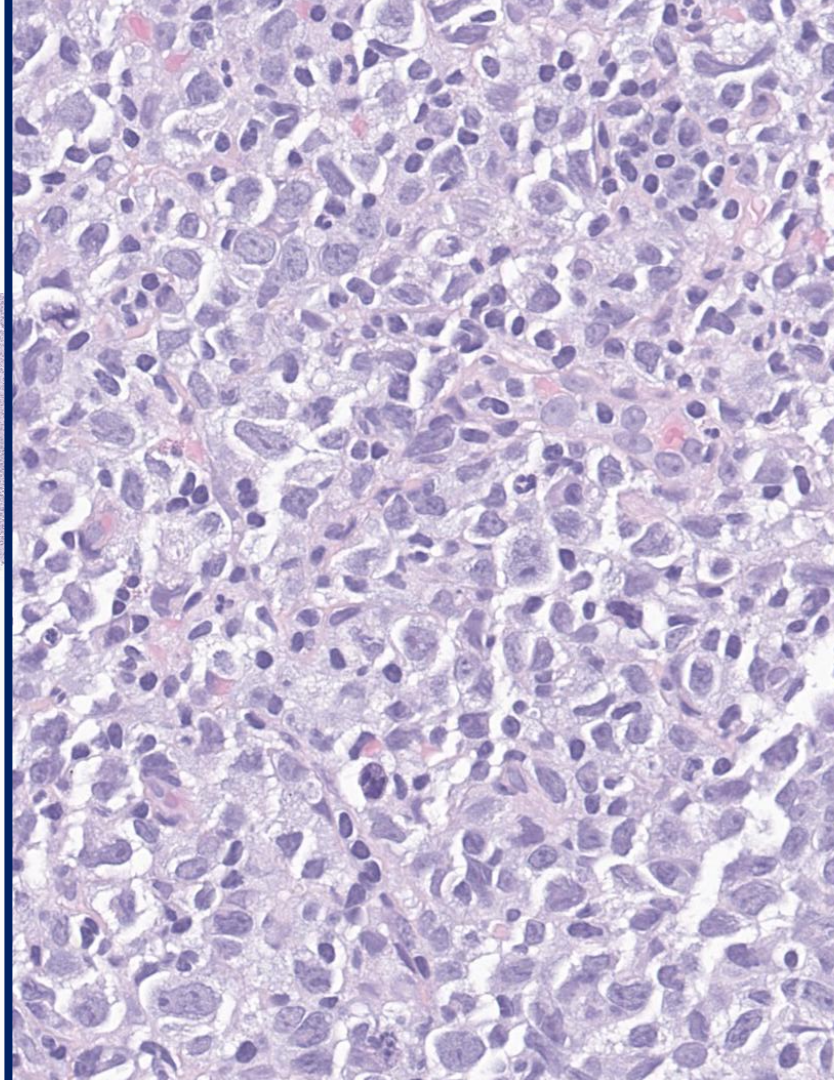
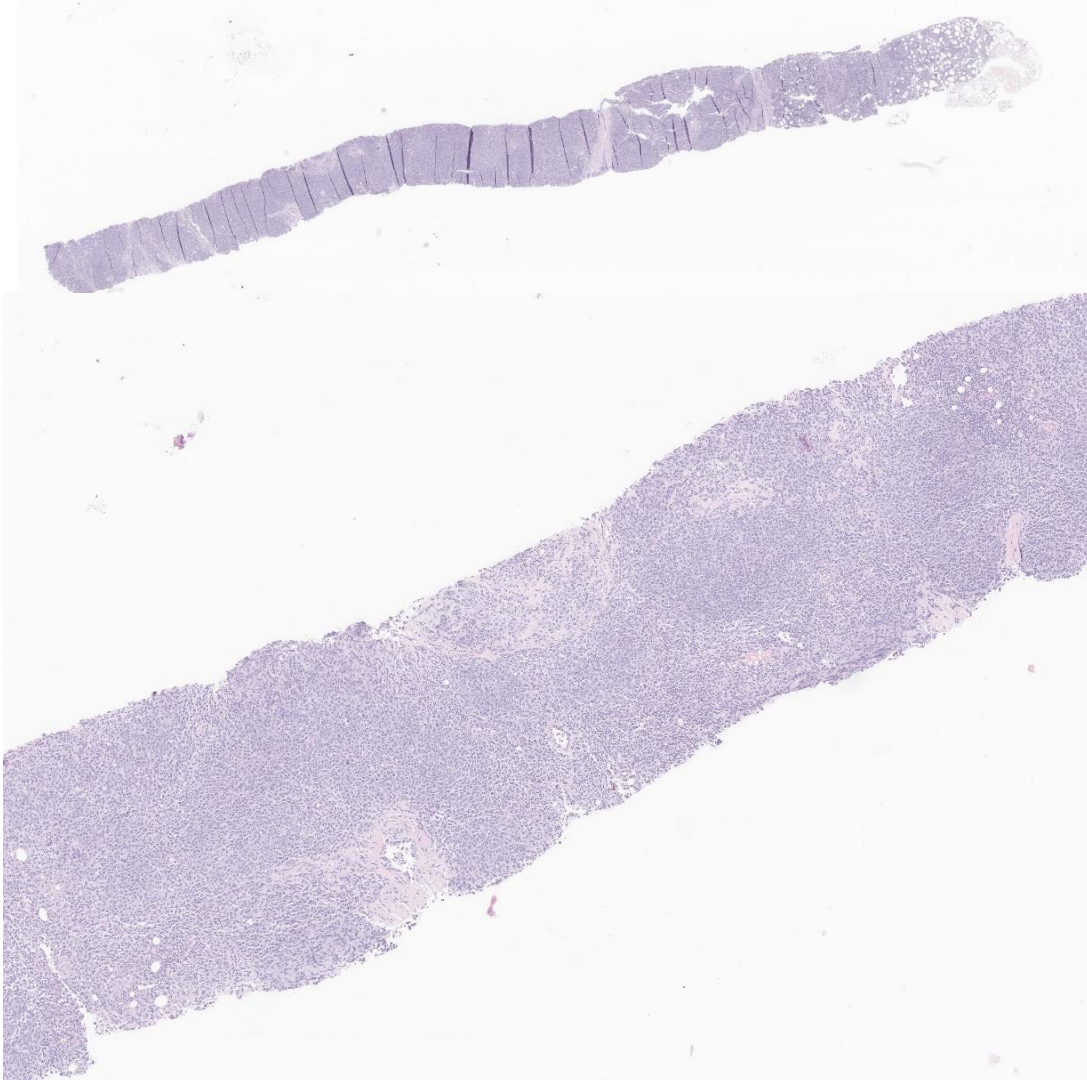
December 2025: staging by PET scan

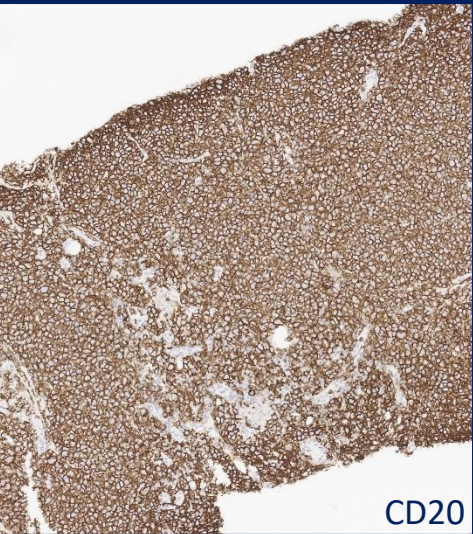
Pulmonary nodule

→ **Cytology: adenocarcinoma**

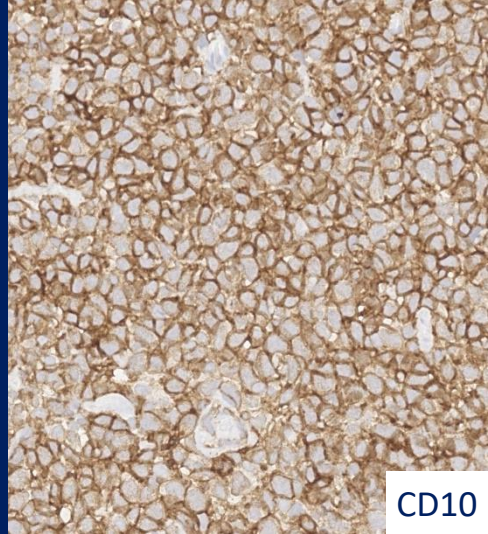
Subcutaneous nodule, posterior aspect of the left leg

→ **Incisional biopsy performed.**

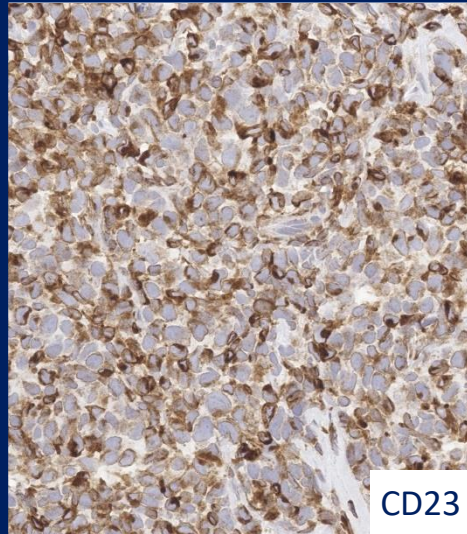




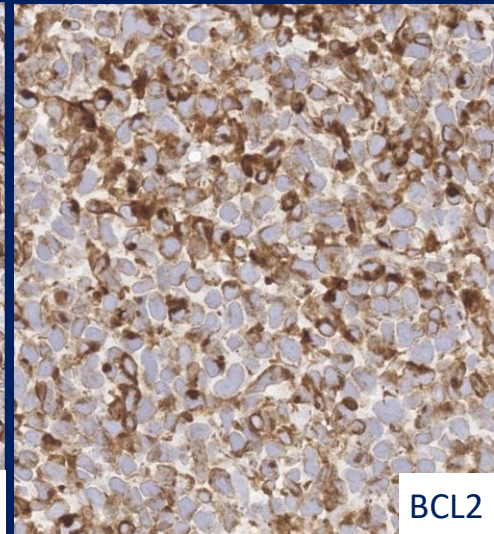
CD20



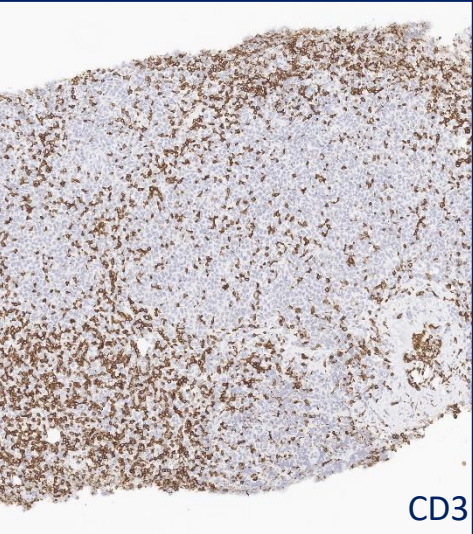
CD10



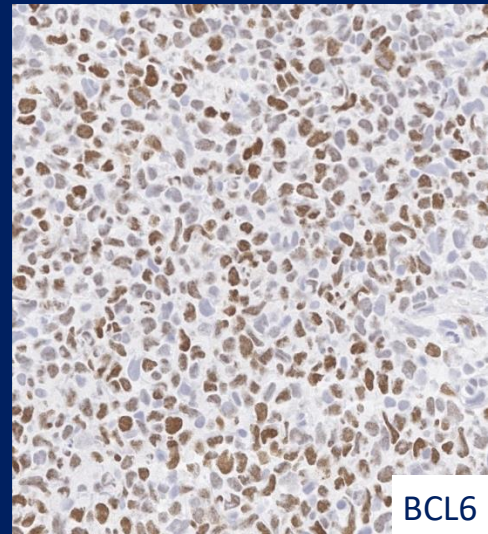
CD23



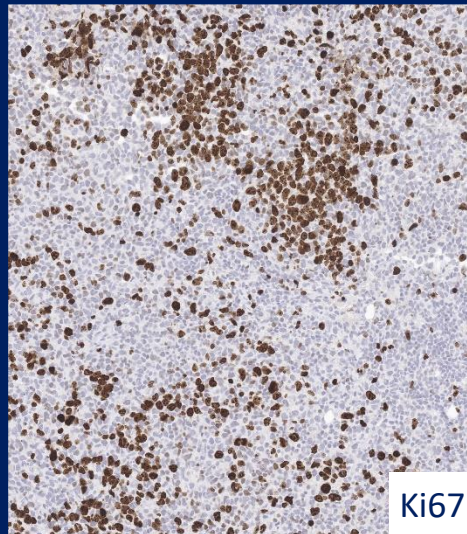
BCL2



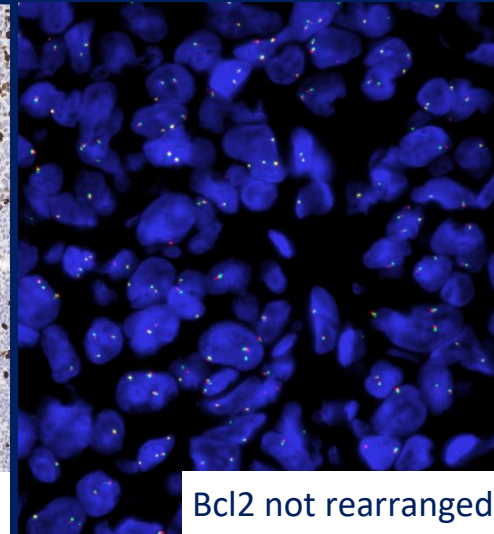
CD3



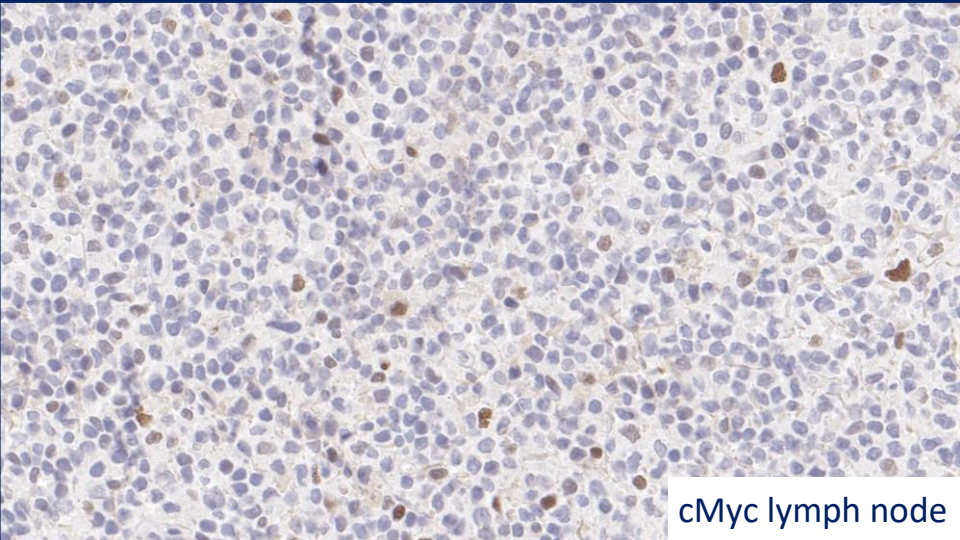
BCL6



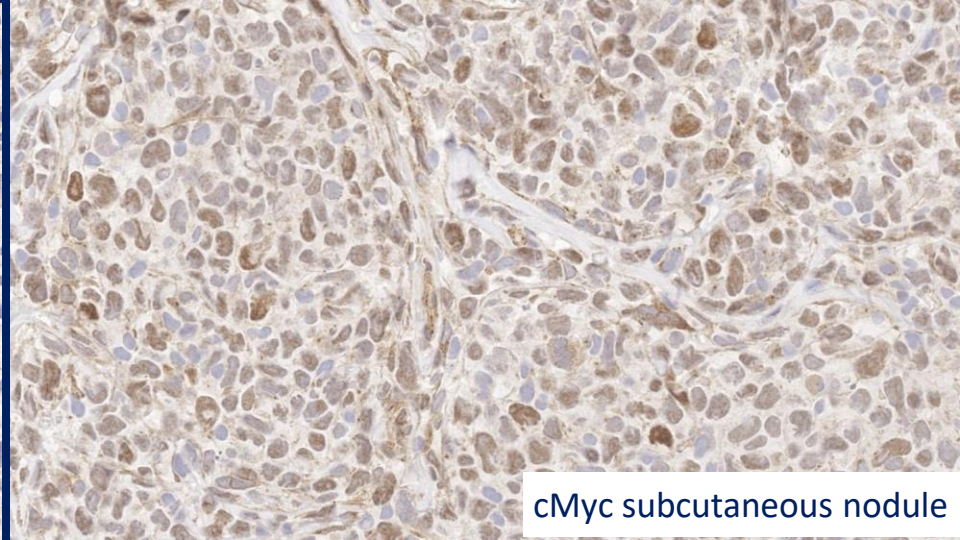
Ki67



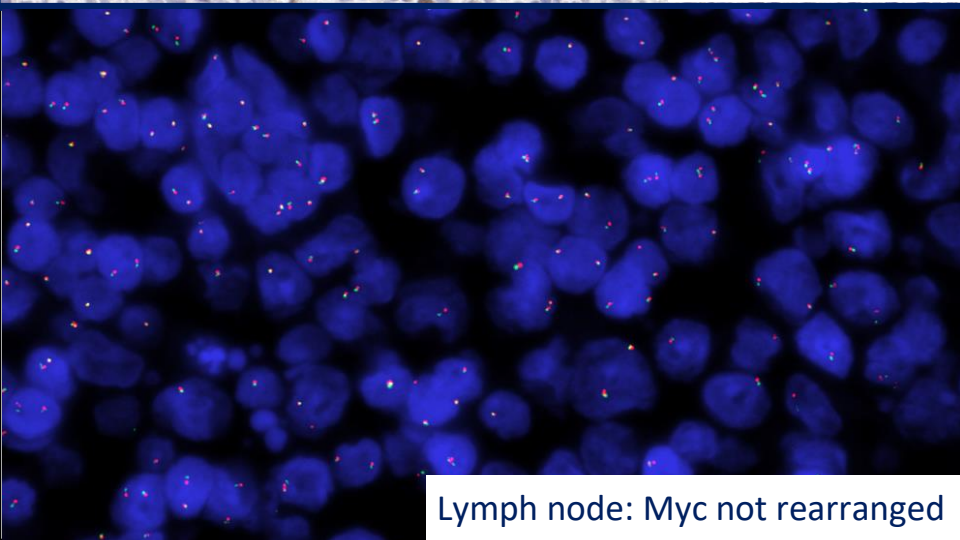
Bcl2 not rearranged



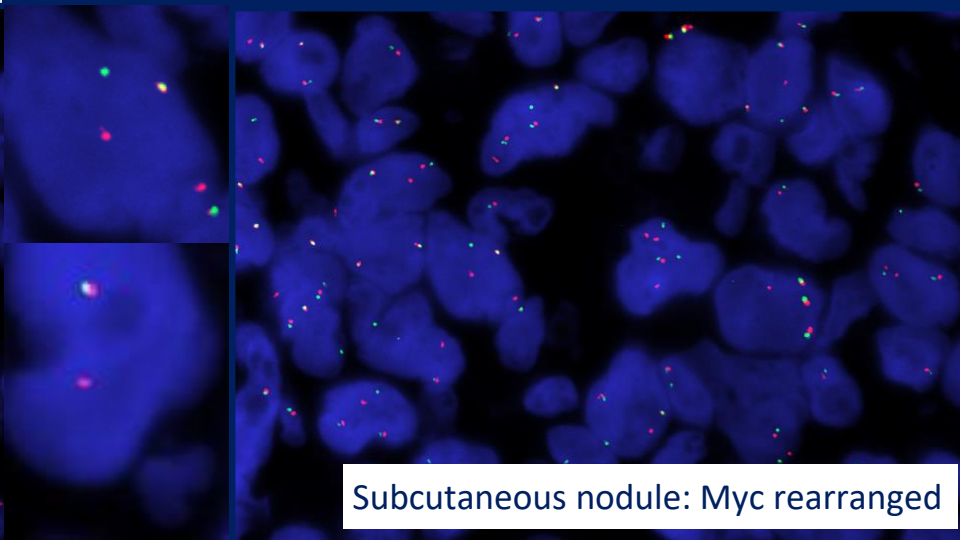
cMyc lymph node



cMyc subcutaneous nodule



Lymph node: Myc not rearranged



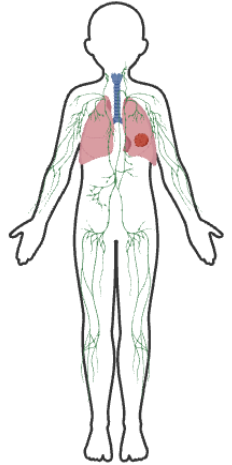
Subcutaneous nodule: Myc rearranged

October 2025: inguinal lymphadenopathy → BCL2R negative CD23 positive follicle centre lymphoma (ICC 2025).

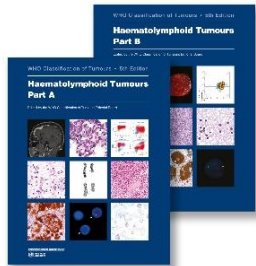
December 2025: Subcutaneous nodule, posterior aspect of the left leg → Localization of BCL2R negative and CD23 positive follicle center lymphoma (ICC 2025), with MYC rearrangement and high Ki67.

Transformation?

January 2026: death due to complications following thoracic surgery.



BCL2-R–negative CD23-positive follicle centre lymphoma (ICC 2025) Follicle centre lymphoma with dominant diffuse growth pattern (WHO 2024)

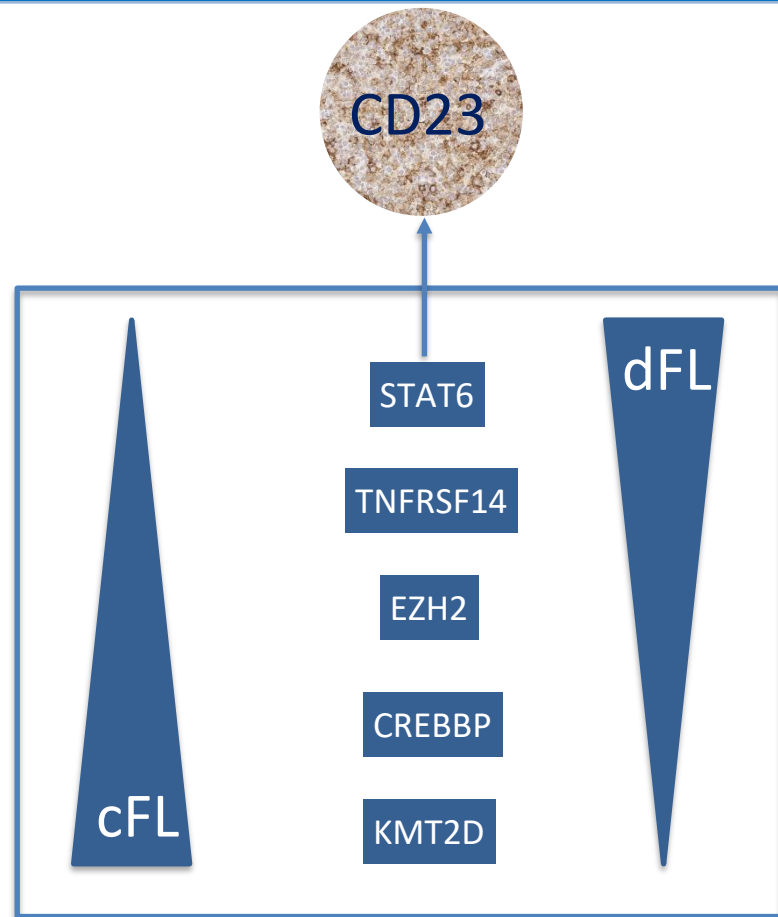


Provisional entity

Grading is not recommended

55 evaluated patients:
71% at diagnosis: Stage I or II
86% survival at 53 months
7% DoD (dead of disease) →
1 transformation into DLBCL

Laurent C. et al., *Adv Anat Pathol.* 2025
Shelton Blood Cancer J. 2024
Nann D et al, *Blood Adv.* 2020



La **DIAGNOSTICA** **EMATOPATOLOGICA** nell'ERA della **MEDICINA** di **PRECISIONE**

Acknowledgments

Luisa Lorenzi

Flavia Melotti

Mattia Facchetti

Giulio Eugenio Mandelli

Piera Balzani

Anna Galvagni